

## Horner's syndrome

Horner's syndrome is not uncommon and occurs in dogs, cats, horses and many other species. The symptoms generally include a sunken in eye (enophthalmia) with a small pupil (miosis), a droopy upper eyelid (ptosis) and a prominent third eyelid.

### What is Horner's syndrome?


There are two major divisions within your nervous system. There is the part of your nervous system that you are aware of and have control over, and there is the part of your nervous system that is under automatic control. The eye has both sympathetic and parasympathetic autonomic innervation. If something were to block the sympathetic impulses into the eye, there would be an over balance of parasympathetic supply to the eye. The result is the pupil will constrict, and all of the muscles around the eye will relax. The eye will sink somewhat into the orbit, the third eyelid will become prominent and the upper eyelid will become droopy. This is Horner's syndrome.

### What causes Horner's?


The nerve that carries sympathetic innervation to the eye takes a remarkable course as it travels from the brain to the eye. The nerve travels down the spinal cord from the brain, emerges in the chest cavity and then finds its way up the neck along with the carotid artery and jugular vein through the middle ear and then into the eye. Horner's syndrome is associated with damage to the sympathetic innervation to the eye. The damage may have numerous causes, and may occur anywhere along the course of the nerve's route from the brain to the eye. Thus Horner's syndrome may be associated with brain tumors, spinal cord injury in the neck, thoracic tumors, injuries to the neck, choke collar injury, middle ear infections, and viral, immune mediated or idiopathic (of unknown cause) neuropathies.

### What is the treatment?

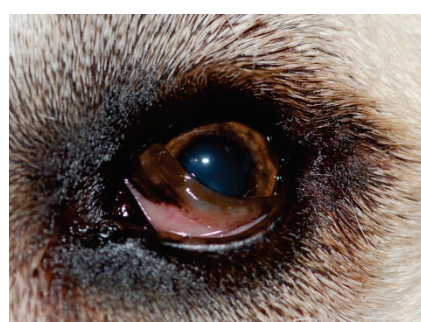
In most cases of idiopathic (unknown cause) Horner's syndrome spontaneous recovery will occur in an average of 6 to 16 weeks. A thorough physical examination is warranted to rule out any of the other causes of Horner's syndrome. If the veterinarian has any suspicion that the cause may not be idiopathic, then it may be prudent to do blood work and a chest x-ray. If idiopathic Horner's syndrome is diagnosed, the clinical signs will progressively improve over time. It is important to know your pet is not in pain. The eye conditions are due to a nerve problem that is not painful.



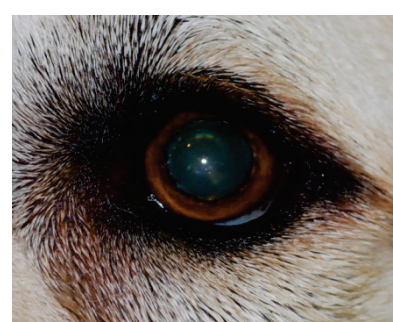
Horner's syndrom in a cat



The same cat 10 minutes after instillation of a drop of phenylephrine: the disappearance of the signs confirms the diagnosis of Horner syndrome



Horner's syndrome in a dog



The same dog 10 minutes after instillation of a drop of phenylephrine: the disappearance of the signs confirms the diagnosis of Horner syndrome